CHEST

An 87-Year-Old Woman With Pleural Effusion and Tortuous Aorta

Bruce Sabath, MD; Rimoun Hakim, MD; and Rex Yung, MD

VIDEO

CHEST 2017; 151(2):e21-e24

Case

An 87-year-old woman with atrial fibrillation, a history of deep venous thrombosis, and a long smoking history was admitted with progressive shortness of breath and productive cough of 2 days' duration with subjective fevers and chills. Vital signs on admission included a respiratory rate of 30 breaths/min and oxygen saturation of 89% on room air. The patient was moderately dyspneic and there was dullness to auscultation and percussion of the left lung base, with mild inspiratory crackles in the left upper lung field.

Chest radiography showed opacification of the lower half of the left thorax consistent with pleural effusion (Fig 1). A subsequent CT scan confirmed the pleural effusion but also demonstrated an aberrant right subclavian artery coursing posterior to the trachea and esophagus (Fig 2). More caudal images from the same CT scan showed a partially consolidated/compressed left lower lobe along with the thoracic aorta abutting the left posterior chest wall in some segments (Fig 3) and crossing sharply toward the midline at a level just above the diaphragm (Fig 4).

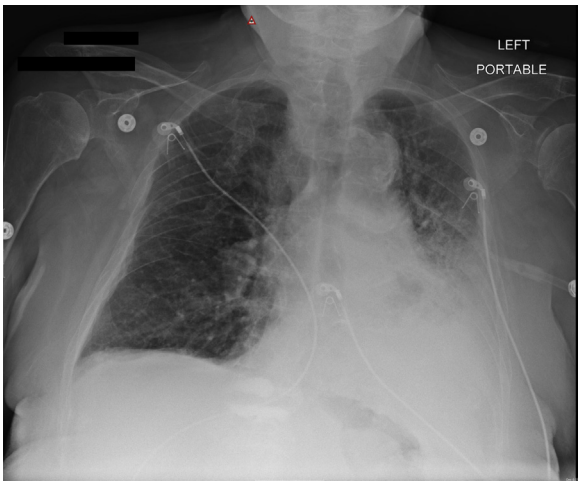

Figure 1 – *Chest radiography demonstrating opacification of the lower left hemithorax, suggesting the presence of pleural effusion.*

Pulmonary consultation was requested for treatment of her pleural effusion. Thoracic ultrasound was performed for further evaluation of the pleural fluid in preparation for diagnostic and therapeutic thoracentesis (Video 1, showing two-dimensional ultrasound of the left thorax, demonstrating lung consolidation and/or compressive atelectasis with surrounding fluid).

Question: Based on the interpretation of Video 1 and other patient data, what is the best next ultrasound modality to use for further evaluation of the left thorax?

AFFILIATIONS: From the Pulmonary and Critical Care Division, Greater Baltimore Medical Center, Baltimore, MD.

CORRESPONDENCE TO: Bruce Sabath, MD, Pulmonary and Critical Care Division, Greater Baltimore Medical Center, 6565 N. Charles St, Ste 411, Baltimore, MD 21204; e-mail: bruce.sabath@gmail.com

Copyright © 2016 American College of Chest Physicians. Published by Elsevier Inc. All rights reserved.

DOI: http://dx.doi.org/10.1016/j.chest.2016.05.043

Downloaded From: http://journal.publications.chestnet.org/pdfaccess.ashx?url=/data/journals/chest/936027/ on 03/30/2017

Answer: Color flow Doppler imaging.

Video 2 shows color flow Doppler imaging of the same space, demonstrating a large pulsatile vessel, consistent with the aorta. This is seen on the CT scan (Figs 3A, 3B) as an unusual position of the aorta.

Discussion

Given the observation on CT scanning that the aorta took a tortuous course and was near the chest wall along some portions of its length, color flow imaging was added to further evaluate the fluid surrounding the patient's consolidated left lower lobe prior to attempting thoracentesis. The fact that this fluid was flowing became apparent, with red color representing upstream movement of blood toward the probe and blue color representing downstream movement of blood away from the probe. Flow was pulsatile as well. Thus, it became immediately apparent that—in this region of the thorax—this fluid seen around the lung just deep to the chest wall was not a pleural effusion but the aorta noted on CT scanning. An alternative site for thoracentesis, where the observed fluid was clearly pleural and not vascular, was then identified by ultrasound. The remainder of the patient's hospital course was uncomplicated, and she was discharged to a physical rehabilitation center prior to going home.

In the last several years, thoracic ultrasonography has become the standard of practice for evaluation of pleural fluid and pleural drainage.[1] It can be used not only for marking a site for entry but also for real-time guidance during a procedure. In addition, multiple studies have demonstrated the superior safety and accuracy that ultrasound provides compared with procedures done without ultrasound.[2-6] Pneumothorax rates for thoracentesis performed without sonographic guidance have ranged from 4% to 30% whereas for those done with ultrasound guidance the rates are almost uniformly less than 5%.[2,3,7-12] Ultrasonography has also been shown to decrease pleural hemorrhage rates, costs of hospitalization, and lengths of stay while also increasing pleural fluid yield.[5,6] One study also demonstrated how ultrasound could prevent accidental organ puncture in up to 10% of cases in which the needle insertion site had initially been chosen by chest radiography and clinical examination alone.[13]

The most common ultrasonographic modality employed in these cases is two-dimensional (2-D) imaging. This can be used to visualize pleural fluid and can demonstrate several characteristics therein including volume, complexity, and location relative to adjacent structures. However, 2-D ultrasound does not readily identify movement of fluid (eg, flow). Doppler techniques such as color flow imaging allow for assessment of blood flow within a given area of interest. Color and color intensity represent direction and velocity of the fluid in question, respectively.[14] Thus, such technology can allow one to distinguish between fluid that is largely stationary (eg, pleural fluid) and fluid in motion (eg, intravascular blood). Doppler ultrasound is not routinely used as part of the examination prior to thoracentesis, although it has been described for evaluation of intercostal vessels.[15]

In our case, the tortuous aorta had the same appearance as pleural fluid often does on 2-D imaging.

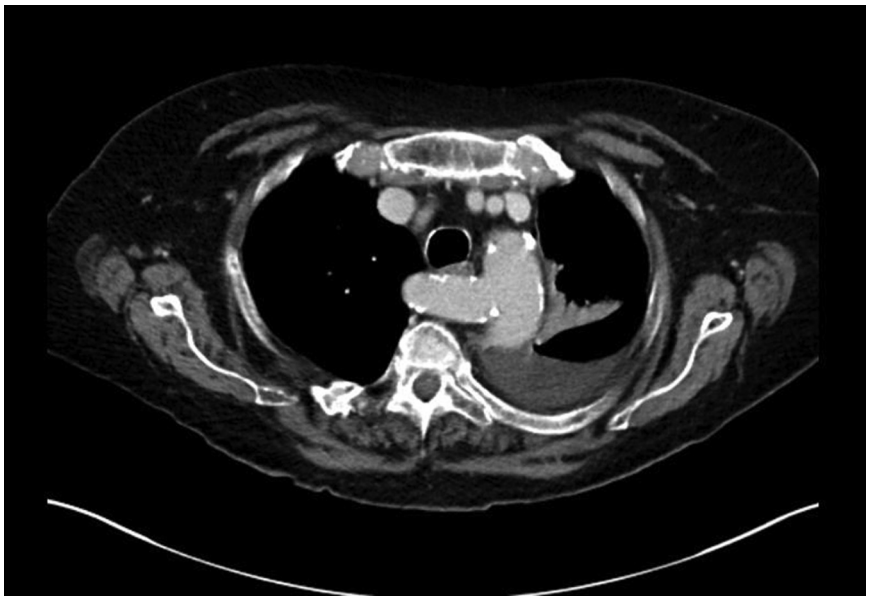

Figure 2 – *CT scan demonstrating the pleural effusion as well as an aberrant right subclavian artery posterior to the trachea and esophagus.*

Downloaded From: http://journal.publications.chestnet.org/pdfaccess.ashx?url=/data/journals/chest/936027/ on 03/30/2017

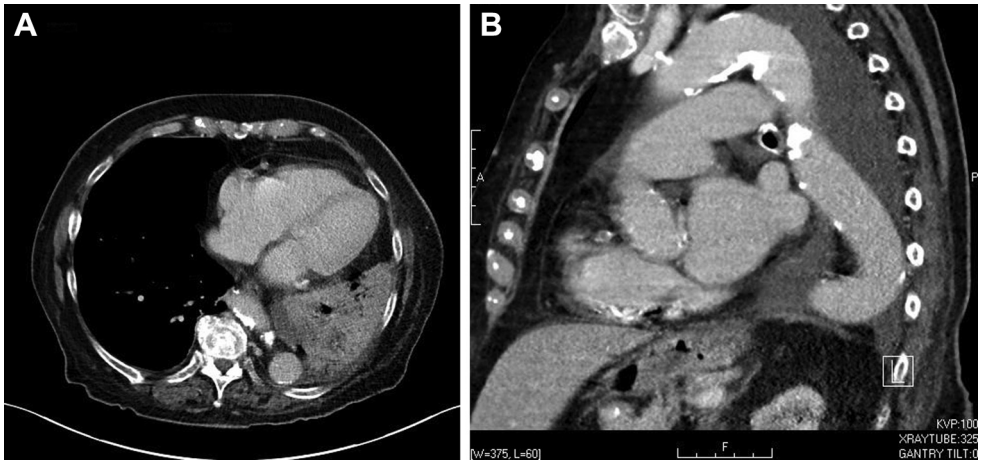

Figure 3 – *CT scan (A, axial view; B, sagittal view), demonstrating the thoracic aorta coursing very near the posterior chest wall just deep to the ribs.*

The posterior wall of the aorta was apposed to the posterior chest wall, making it difficult to see that the visible fluid was not free-flowing in the pleural space but, rather, was blood in the lumen of a large vessel. Even observing some pulsatility on the image did not clearly suggest the presence of a vessel because the beating of the heart often causes an atelectatic left lung to move in a cardiophasic fashion, a finding termed "lung flapping" or the "jellyfish sign."[16] In essence, in an effort to identify the pleural effusion in this patient, it was not sufficient to take the usual approach of looking for an anechoic space with the relevant landmarks (ie, hemidiaphragm, chest wall, and lung). This typical anatomic location for thoracentesis required further evaluation with additional ultrasonographic modalities.

In our case, the preceding CT scan informed us of the presence of the aorta adjacent to both the chest wall and the pleural effusion. However, in many cases, CT scanning is not done before proceeding with thoracentesis. As mentioned previously, chest radiography alone without ultrasound had been the common practice prior to thoracentesis. As the current

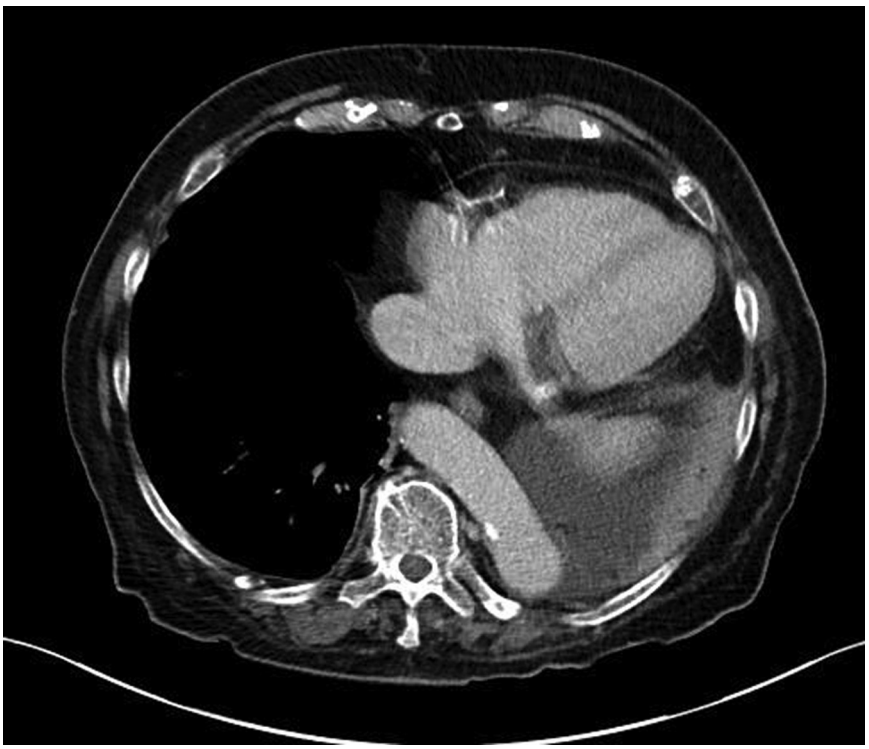

Figure 4 – *More inferiorly, the aorta crosses sharply toward the midline at a level just superior to the diaphragm.*

Downloaded From: http://journal.publications.chestnet.org/pdfaccess.ashx?url=/data/journals/chest/936027/ on 03/30/2017

standard, ultrasound is often performed after radiography, but usually only in the 2-D modality. The unusual aortic anatomy in this case produced a sonographic 2-D image similar to that of most free-flowing pleural fluid surrounding an atelectatic left lung, including the observed pulsatility. Had it not been for the CT scan, there would not have been any clear evidence that the fluid seen on ultrasound was intravascular rather than pleural and thoracentesis may have been attempted—likely with catastrophic results. Here we report a case in which using color flow imaging of the pleural space—rather than simple 2-D imaging alone—significantly changed treatment and, likely, outcome.

The Discussion (Video 3) is a compilation of Videos 1 and 2 as well as a segment demonstrating the lung-flapping sign in another area of this patient's thorax where there was no aorta—showing how pulsatility is seen even when no arterial structures are immediately adjacent to the lung (intended to refute the possible response that the pulsatility observed should have made it obvious that the fluid was in a vessel rather than pleural fluid). Finally, for comparison, a segment from another patient is shown, demonstrating the usual location of the aorta relative to the pleural fluid.

Reverberations

1. *Given the presence of anatomic variants—particularly the common tortuosity of the thoracic aorta—fluid noted to be surrounding the lung by 2-D ultrasound should not be presumed to be pleural in nature in all cases.*
2. *Particularly when thoracentesis is to be performed after chest radiography alone (eg, without prior CT scan), color flow imaging is a useful adjunct to 2-D imaging for further evaluation of what is suspected to be pleural fluid prior to needle insertion.*
3. *The addition of color flow imaging to pleural ultrasound is easily performed and does not prolong the procedure to any significant degree.*

Acknowledgments

Financial/nonfinancial disclosures: None declared.

Other contributions: *CHEST* worked with the authors to ensure that the Journal policies on patient consent to report information were met.

Additional information: The Videos can be found in the Supplementary Materials section of the online article.

References

1. Havelock T, Teoh R, Laws D, et al. Pleural procedures and thoracic ultrasound: British Thoracic Society pleural disease guidelines 2010. *Thorax*. 2010;65(suppl 2):ii61-ii76.
2. Grogan DR, Irwin RS, Channick R, et al. Complications associated with thoracentesis: a prospective, randomized study comparing three different methods. *Arch Intern Med*. 1990;150(4):873-877.
3. Barnes TW, Morgenthaler TI, Olson E, et al. Sonographically guided thoracentesis and rate of pneumothorax. *J Clin Ultrasound*. 2005;33(9):442-446.
4. Gordon CE, Feller-Kopman D, Balk EM, et al. Pneumothorax following thoracentesis. *Arch Int Med*. 2010;170(4):332-339.
5. Patel PA, Ernst FR, Gunnarsson CL. Ultrasonography guidance reduces complications and costs associated with thoracentesis procedures. *J Clin Ultrasound*. 2012;40(3):135s-141s.
6. Kohan JM, Poe RH, Israel RH, et al. Value of chest ultrasonography versus decubitus roentgenography for thoracentesis. *Am Rev Respir Dis*. 1986;133(6):1124-1126.
7. Bartter T, Mayo PD, Pratter MR, Santarelli RJ, Leeds WM, Akers SM. Lower risk and higher yield for thoracentesis when performed by experienced operators. *Chest*. 1993;103(6):1873-1876.
8. Seneff MG, Corwin RW, Gold LH, Irwin RS. Complications associated with thoracocentesis. *Chest*. 1986;90(1):97-100.
9. Doyle JJ, Hnatiuk OW, Torrington KG, Slade AR, Howard RS. Necessity of routine chest roentgenography after thoracentesis. *Ann Intern Med*. 1996;124(9):816-820.
10. Jones PW, Moyers JP, Rogers JT, Rodriguez RM, Lee YC, Light RW. Ultrasound-guided thoracentesis: is it a safer method? *Chest*. 2003;123(2):418-423.
11. Mayo PH, Goltz HR, Tafreshi M, et al. Safety of ultrasound-guided thoracentesis in patients receiving mechanical ventilation. *Chest*. 2004;125(3):1059-1062.
12. Lichtenstein D, Hulot JS, Rabiller A, et al. Feasibility and safety of ultrasound-aided thoracentesis in mechanically ventilated patients. *Intensive Care Med*. 1999;25(9):955-958.
13. Diacon AH, Brutsche MH, Soler M. Accuracy of pleural puncture sites: a prospective comparison of clinical examination with ultrasound. *Chest*. 2003;123(2):436-441.
14. Narasimhan M, Koenig SJ, Mayo PH. Advanced echocardiography for the critical care physician. Part 1. *Chest*. 2014;145(1):129-134.
15. Koyanagi T, Kawaharada N, Kurimoto Y, et al. Examination of intercostal arteries with transthoracic Doppler sonography. *Echocardiography*. 2010;27(1):17-20.
16. Cardenas-Garcia J, Mayo PH, Folch E, et al. Ultrasonographic evaluation of the pleura. *Pleura*. 2015;2:1-11.

Downloaded From: http://journal.publications.chestnet.org/pdfaccess.ashx?url=/data/journals/chest/936027/ on 03/30/2017